

**PATIENT**

Jasmine Downey

SPECIES

Canine

BREED

Jack Russell Terrier

SEX

Female Spayed

AGE

4.9.07

WEIGHT

8.98lbs

PRESENTING CLINICAL SIGNS

History: Recheck echo. Heart murmur, grade 5/6 with PMI on L but able to auscult bilaterally.

-Pertinent abnormal PE/Chem/CBC/UA Results: 11/2022 bloodwork: CBC: elevated platelets (583)
 CHEM: azotemia: SDMA 18, Creat 2.0, bun 53 (IRIS stage 2- mild azotemia). UA: pending submission.
 T4: 2.2 WNL.

-Current medications: Gabapentin 50mg- 1 PO BID-TID PRN for pain. Pimobendan 2.5mg: 1/2 PO BID.
 -Sedation used: Not required to complete full diagnostic ultrasound.

-Pertinent previous ultrasound results (2/2022 MML): Moderate MR, mild LVE, moderate LAE, mild TR, mild PAH. LA: 2.4, LV: 3.4, TR: 3.0.

-STAT: Not requested

-Imaging performed by: Andi Parkinson, BS, RDMS.

ECHOCARDIOGRAM FINDINGS

2D, m-mode, color flow and doppler imaging is available. Diffuse thickening of mitral valve with significant prolapse of the anterior leaflet into the lumen. Moderate eccentric mitral regurgitation with mild to moderate left atrial dilation. Elevated MR velocity. Mildly increased LV diameter with hyperdynamic myocardial function. The tricuspid valve appears mildly thickened with mild tricuspid regurgitation. Velocity consistent with early pulmonary hypertension. Normal right atrial and ventricular diameter. The pulmonic and aortic valves are normal in morphology and mobility. Normal pulmonic and aortic outflow velocities. No aortic or pulmonic insufficiency. No pericardial or pleural effusion noted. No cardiac tumors observed.

CARDIAC CHART**INTERPRETED BY**

Maggie Machen Lamy,
 DVM, DACVIM
 (Cardiology)

HOSPITAL NAME

Perry Hall Animal
 Hospital

REFERRING VET

Dr. Bredidenbaugh

INVOICE

29133

DATE

2.21.23

| CANINE CARDIAC PARAMETERS | MR VMAX (m/s) | TR VMAX (m/s) | LA/AO (Boon method) | LA/AO (Heart Base; Swe) | FS (%) | EF (%) | EPSS (cm) |
|---|-------------------------|-------------------------|-------------------------------|-----------------------------------|---|---|---|
| NORMAL PARAMETER | 4.5-5.5 | <2.7 | 1.3 | <1.6 | 28-40 | 40-100 | <0.6 |
| PATIENT | 5.5 | 3.0 | NM | 1.55 | 51 | 84 | NM |
| CANINE CARDIAC PARAMETERS | HR (BPM) | AV VMAX (m/s) | PV MAX (m/s) | BODY WEIGHT (kg) | LA 2D short axis Base view (cm) | LVIDd Avg; 2D and m-mode short axis (cm) | LVIDs Avg; 2D and m-mode short axis (cm) |
| NORMAL PARAMETER | 50-100 | 0.7-1.7 | 0.7-1.6 | BELOW | BELOW | BELOW | BELOW |
| PATIENT | 125 | 1.4 | 1.0 | 4.1 | 2.1 | 2.8 | 1.4 |
| *Normal chamber parameters expressed as a mean value (SD) | | | | 3 | 1.27 (5.3) | 2.46 (2.46) | 1.36 (5.5) |
| BODY WEIGHT DEPENDENT PARAMETERS | | | | 5 | 1.40 (4.5) | 2.74 (5.2) | 1.60 (4.7) |
| <i>*Note: All measurements based upon multi-modal images and methods. An average value is reported.</i> | | | | 10 | 1.50 (3.8) | 3.27 (3.5) | 2.06 (3.1) |
| | | | | 15 | 1.83 (2.0) | 3.71 (2.4) | 2.43 (2.1) |
| | | | | 20 | 2.02 (1.9) | 4.14 (2.2) | 2.80 (2.0) |
| | | | | 25 | 2.18 (2.4) | 4.48 (2.9) | 3.10 (2.5) |
| | | | | 30 | 2.33 (3.3) | 4.83 (3.9) | 3.39 (3.4) |
| | | | | 35 | 2.48 (4.3) | 5.17 (5.0) | 3.69 (4.5) |
| | | | | 40 | 2.62 (5.2) | 5.48 (6.1) | 3.96 (5.4) |
| | | | | 50 | 2.88 (7.1) | 6.07 (8.3) | 4.46 (7.4) |

Adapted from June Boon, Veterinary Echocardiography, 1998
 Rishniw M and Hollis NE, J Vet Intern Med 2000; 14:429-435
 Hansson et al, Vet Rad and Ultrasound 2002
 Bonagura et al. Echocardiography: principles of interpretation, Vet Clin North Am 15:1177, 1995

INTERPRETATION OF THE FINDINGS & FURTHER RECOMMENDATIONS

Chronic degenerative valve disease persists with evidence of stability. Moderate mitral and mild tricuspid regurgitation are unchanged, without progressive left heart enlargement. Persistently moderate left atrial enlargement indicates there is relatively low risk for imminent complication; however, risk for progression to spontaneous congestive heart failure in the future is elevated. Early pulmonary hypertension is stable. No additional issues are identified.

Reasonable to continue Pimobendan lifelong as prescribed with no obvious indication for additional medications. Continued assessment of progression is recommended, with a guarded prognosis (stage B2). Patient may be at risk for development of CHF, arrhythmias, and/or sudden death going forward.

Omega fatty acid supplementation and mild salt restriction may also be of some long term benefit. Monitor for development of a progressive cough, labored breathing, exercise intolerance or collapse episodes.

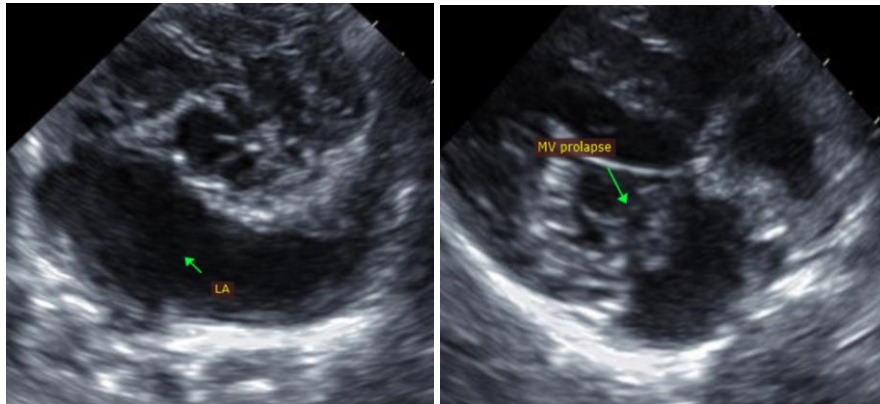
Anesthetic risk remains mildly elevated. Cardiac protective drug choices (opioid/benzodiazepine premedication, Propofol or alfaxalone induction, iso or sevo gas) are recommended. Monitor for arrhythmias, hypotension, and hypoxia both intra and post-operatively and intervene as necessary. Judicious IV fluid rates are recommended to avoid fluid overload. Avoid heart rate stimulating drugs such as atropine unless clinically indicated.

PLAN

Baseline BP recommended every 6 months. Continue Pimobendan 0.25-0.3mg/kg PO q12h.

Recommend monitor for progression with a recheck echocardiogram in 6 months, sooner if any development of clinical signs.

IMAGES



The information and recommendations provided are based on the images presented by the referring veterinarian. No evaluation can be communicated regarding pathology that was not visible in the image/video clips provided.

Thank you for this referral. This report was generated using transcription software, and minor dictation errors may be present. If the clinical or image interpretation does not parallel your findings or if I can be of any further assistance please contact me.

Maggie Machen Lamy, DVM
Diplomate of the American College of Veterinary Internal Medicine (Cardiology)
info@sonopath.com